ACCURAY

CASE STUDY

T6 SPINAL SOLITARY BREAST METASTASIS

UPMC HEALTH SYSTEM

University of Pittsburgh Medical Center CyberKnife® Team:

Surgeon:	Peter C. Gerszten, M.D., M.P.H.
Radiation Oncologist:	Steven A. Burton, M.D.
Medical Physicist:	Cihat Ozhasoglu, Ph.D.
Radiation Therapist:	William J. Vogel, R.T.(T.)
Nurse:	Annette E. Quinn, R.N.
CyberKnife Center:	Shadyside Hospital University of Pittsburgh Medical Center Pittsburgh, PA

ACCURAY CyberKnife

T6 SPINAL SOLITARY BREAST METASTASIS

DEMOGRAPHICS		CLINICAL HISTORY	
Sex:	F	**Referred by:**	Medical Oncology
Age:	56	**Previous Treatment:**	External beam radiation of 30 Gy in 10 fractions to the T6 vertebral body
Histology:	Breast Metastasis to T6		

Case History

The patient originally was diagnosed with a T2, N0 infiltrating ductal carcinoma of the right breast. Her cancer was treated with segmental resection. This was followed by radiation therapy to the breast to 61.2 Gy and four cycles of adjuvant 5-FU and methotrexate. Six years later, she presented to her medical oncologist with complaints of back pain. MR imaging revealed a solitary destructive lesion of the T6 vertebral body. Further workup failed to demonstrate other areas of metastatic disease. This solitary metastatic lesion was treated with external beam radiation in ten fractions to 30 Gy with temporary improvement in her symptoms.

However, a month later, persistent symptoms of pain prevented the patient from returning to work and interfered with her activities of daily living. She was therefore referred to the CyberKnife® Spine Center for further evaluation.

Her MRI showed tumor progression with significant compression of the spinal cord at the T6 level. She had no neurological deficits.

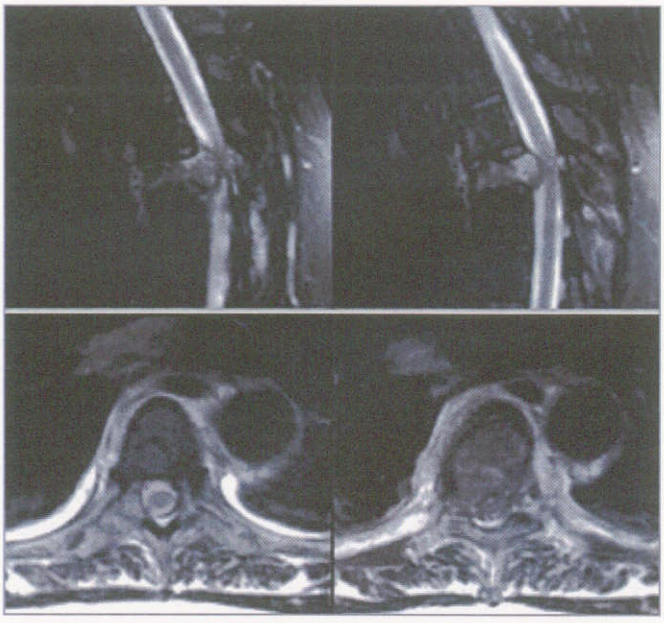

Pretreatment MR: Sagittal T2 weighted and axial T1 weighted gadolinium-enhanced MRI reveals a pathologic compression fracture with significant spinal canal compromise.

CyberKnife Treatment Rationale

The treatment of both malignant as well as benign tumors of the spine using CyberKnife radiosurgery began in 1997. Treatment of spine lesions using single fraction radiosurgery has been a successful treatment strategy at UPMC over the past four years.[1,2,3]

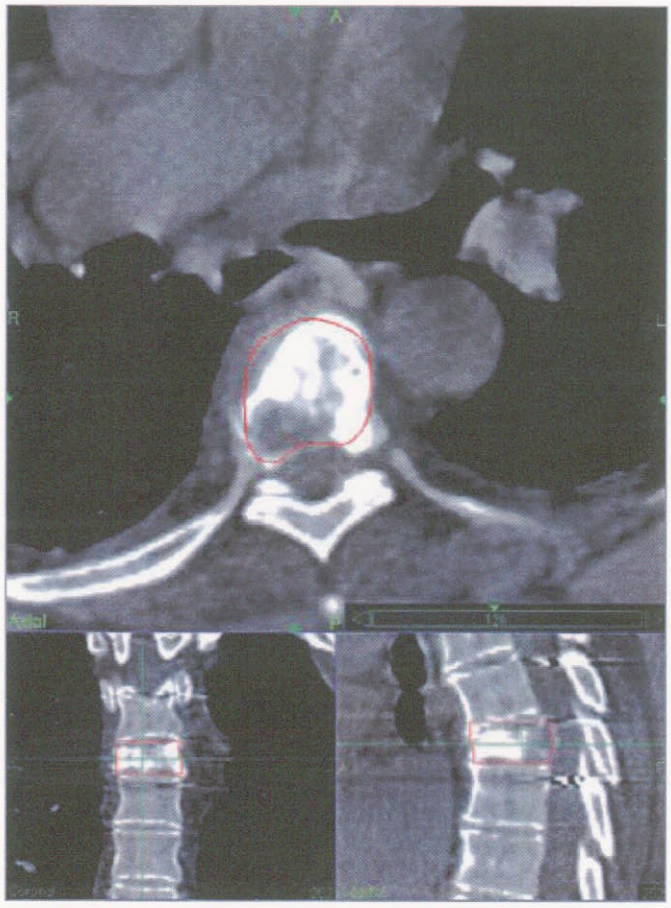

Pretreatment CT showing the outlined tumor at the T6 level. This image set was used for treatment planning and stereotactic radiosurgical targeting on the CyberKnife System.

TREATMENT DETAILS

Tumor Volume:	10.3 cc	**Fractions / Treatment Time:**	1 fraction in 65 minutes
Imaging Technique(s):	CT, T2-MRI , MRI+C	**Path Template:**	1 path 900_1000 mm
Rx Dose & Isodose:	16 Gy to 80%	**Tracking Method:**	Tracking with 5 fiducials
Conformality Index:	1.14	**Collimator(s):**	15 mm
Tumor Coverage:	72.7% of PTV		
Number of Beams:	103		

Planning Process and Goals

The tumor target volume of 10.3 cc was contoured to include the tumor at the level of the T6 vertebral body. Surrounding critical structures, including the spinal cord and esophagus, were contoured to minimize dose to those radiosensitive structures. The 80% isodose line represents the prescribed dose of 16 Gy to the tumor. The prescription isodose line covered 72.7% of the planning target volume with a conformality index of 1.14.

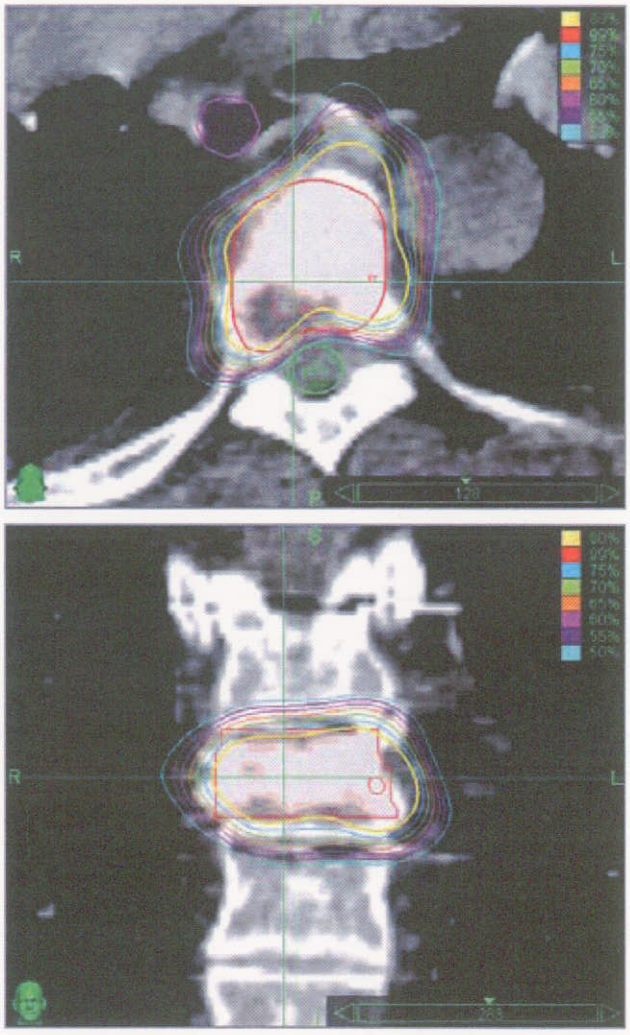

Axial and coronal planning images with the tumor, isodose curves and critical structures outlined. Note the highly conformal dose distribution avoids the critical spinal cord and esophagus at the level of T6 as seen in the axial view.

Treatment Delivery

The treatment utilized 103 separately targeted beams with the 15 mm collimator. The tumor volume measured 10.3 cc and only 0.3 cc of the spinal cord received greater than 8 Gy, consistent with the low conformality index. The patient reported no adverse side effects from the treatment delivery.

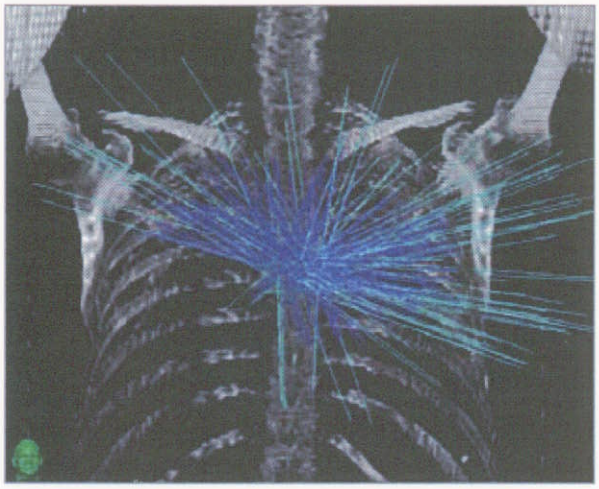

Anterior-posterior rendering of the CyberKnife® System's beam positions for this treatment.

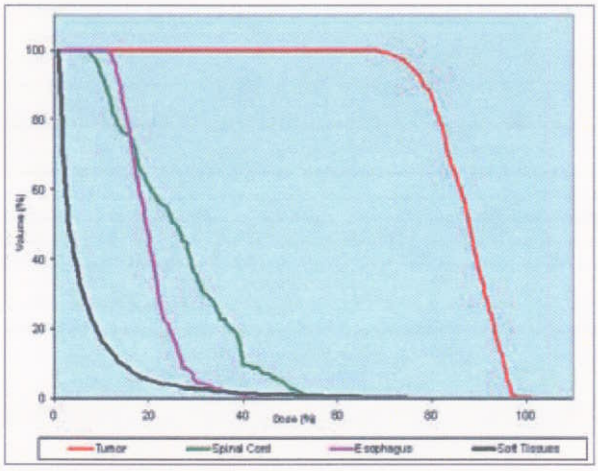

Dose Volume Histogram (DVH) for tumor and critical structures - cord and esophagus.

Outcome and Follow-Up

The patient was followed-up one month after completing CyberKnife® radiosurgery.

- The patient experienced significant pain relief within one month
- She had no new neurological deficits
- One-month follow-up MRI revealed a decrease in tumor volume within the spinal canal and a significant decompression of the spinal cord (below right)
- There is no evidence of further vertebral body collapse
- The patient continues to experience pain relief at four months

Conclusion and CyberKnife Advantages

- The CyberKnife System can deliver a single high-dose of radiation, limiting the dose to the adjacent spinal cord, unlike conventional radiation therapy[4]
- The major benefits of single fraction radiosurgery are a relatively short treatment time in an outpatient setting delivered in a minimally invasive fashion with good clinical response[4]
- Reduction in spinal pain after CyberKnife radiosurgery has been shown to be a major benefit to patients in this as well as in other centers[4,5]

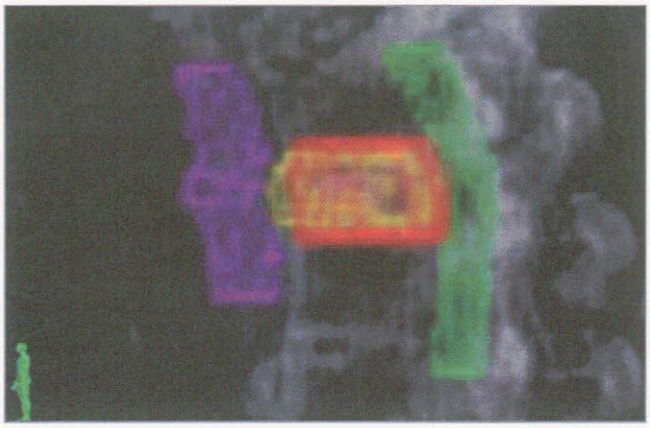

3D (LAO) rendering of target volume (red), prescription volume (yellow) and 2 critical structures – spinal cord (green) and esophagus (purple).

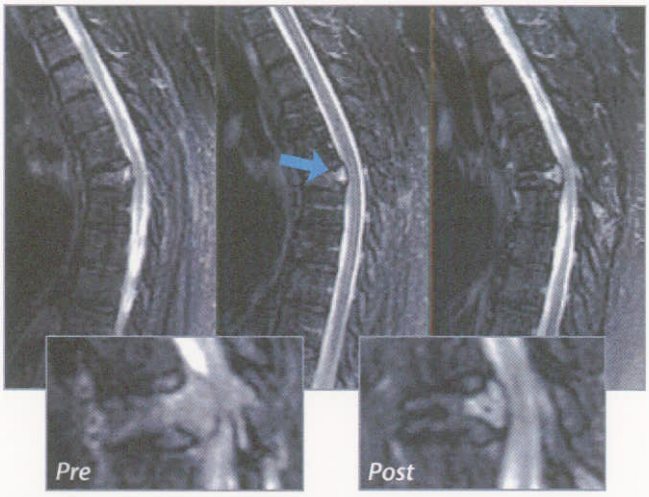

One-month follow-up T2 weighted MRI shows decompression of the spinal cord (arrow). Pre- and post comparison (insert), dramatically demonstrates the benefits of this radiosurgical procedure in this case.

CYBERKNIFE SYSTEM AT UNIVERSITY PITTSBURGH MEDICAL CENTER / SHADYSIDE HOSPITAL (www.upmc.com)

The University of Pittsburgh Medical Center (UPMC) is an internationally renowned medical center and a pioneer in radiosurgery. The CyberKnife Spinal Radiosurgery Program began at UPMC in 2001 under the direction of Dr. Peter Gerszten and Dr. Steven Burton. The UPMC CyberKnife program is the most active spinal radiosurgery program in the United States.[4] This program's team has treated over 800 spinal lesions using a single-fraction radiosurgery technique. Spinal radiosurgery is used as an important adjunct in the treatment of patients with a wide variety of spinal neoplasms.

References

1. Ryu SI, Chang SD, Kim DH, Murphy MJ, Le Q, Martin DP, Adler Jr, JR: Image-guided hypo-fractionated stereotactic radiosurgery to spinal lesions. Neurosurgery, 49(4):838-846, October 2001.
2. Gerszten PC, Ozhasoglu C, Burton SA, Kalnicki S, Welch WC: Feasibility of frameless single-fraction stereotactic radiosurgery for spinal lesions. Neurosurgical Focus, 13(4):e2, October 2002.
3. Gerszten PC, Welch PC: CyberKnife radiosurgery for metastatic spine tumors. Neurosurg Clin N Am, 15(4):491-501, October 2004.
4. Gerszten PC, Burton SA, Ozhasoglu C, Welch WC: Radiosurgery for spinal metastases: clinical experience in 500 cases from a single institution. Spine, 32:193-199, January 2007.
5. Degen J, Gagnon G, Voyadzis JM, McCrae D, Lundsten M, Molzahn I, Dieterich S, Henderson FC: CyberKnife stereotactic radiosurgical treatment of spinal tumors controls pain and maintains quality of life. Journal of Neurosurgery: Spine, 2: 540-549, May 2005.

ACCURAY

ACCURAY CyberKnife

www.accuray.com

© 2007 Accuray Incorporated. All Rights Reserved. Accuray, the stylized logo, CyberKnife, Synchrony, Xsight, Xchange and RoboCouch are among the trademarks and/or registered trademarks of Accuray Incorporated in the United States and other countries. 500101.A