

RECURRENT RECTAL CARCINOMA



Erasmus University Medical Center CyberKnife Team:

Radiation Oncologists

J. Nuyttens, M.D., Ph.D.
Prof. P. Levendag, M.D., Ph.D.
P. Nowak, M.D., Ph.D.
J. Praag, M.D.
A. Mendez Romero, M.D.

Medical Physicists:

H. Marijnissen, Ph.D.
M. Hoogeman, Ph.D.

CyberKnife Center:

Erasmus University Medical Center
Daniel den Hoed Cancer Center
Rotterdam, Netherlands

RECURRENT RECTAL CARCINOMA

DEMOGRAPHICS:

Sex: M
Age: 62
Histology: Recurrent Rectal Carcinoma
Treat Date(s): April 2005

CLINICAL HISTORY:

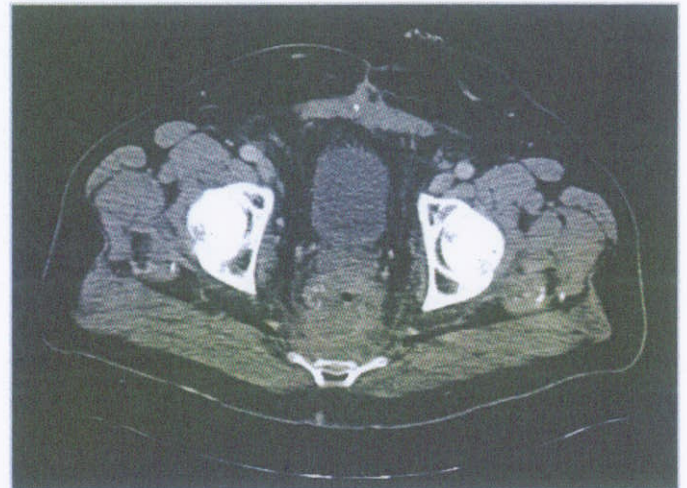
Referred by: Radiation Oncologist
Previous Treatment: Surgery, Radiation Therapy

Case History:

This patient presented in 2001 with a pT3 pN1 rectal adenocarcinoma. A surgical resection was performed followed by external beam radiation therapy (25 x 2Gy) using a three field technique. In 2002 a local recurrence was detected at the surgical scar site, and this was treated using a single electron field (30 x 2Gy). In 2004 a further recurrence was detected distal to the original treatment site, in the anal stump. This was treated with further radiation therapy (15 x 2Gy) using a three field technique. The lesion was found to be inoperable on open examination. In March 2005 the patient presented again with pain in the sacrum and coccyx, which also radiated into the right leg. He also described pain in the anus. He had anal fluid discharge, and had daily anal bleeding episodes.

CyberKnife Treatment Rationale:

A CT scan of the thorax, abdomen and pelvis showed no evidence of metastatic disease, and so chemotherapy was not considered to be appropriate. The lesion was already known to be surgically inoperable, and further conventional radiation therapy was not possible because of the high doses already delivered to a large volume. CyberKnife radiosurgery was considered to be safe in this case given the high conformality and dose gradient achieved. Treatment was delivered with the intention of palliating the pain symptoms and reducing rectal bleeding.



Pre-treatment CT, showing a large rectal lesion adjacent to both the bladder and cauda equina. The hypo-dense region at the center of the lesion is an area of infection, responsible for the fluid discharge.

RECURRENT RECTAL CARCINOMA

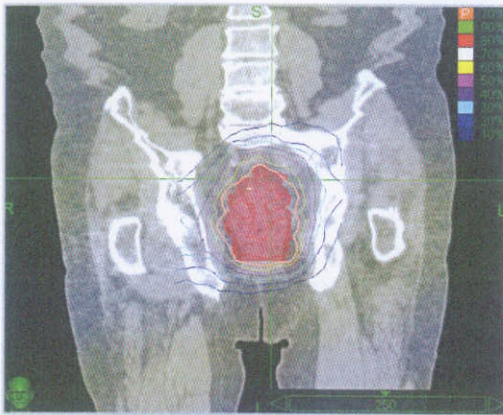
TREATMENT DETAILS:

Tumor Volume: 294 cm³
Imaging Technique(s): CT
Rx Dose & Isodose: 16 Gy to 70%
Conformality Index: 1.44
Tumor Coverage: 98.1%

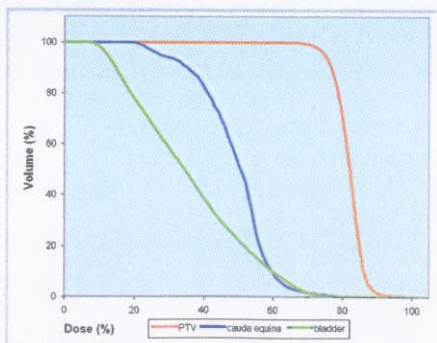
Fractions / Treatment Time: 2 / 2 hours per fraction
Path Template: 3 paths 900_1000 mm
Tracking Method: Fiducial Tracking
Collimator(s): 12.5 mm and 40 mm
Number of Beams: 232

Treatment Planning Process:

Four fiducial markers were implanted under local anesthesia without complication. A planning CT was acquired with the patient in the prone position. The Clinical Target Volume was defined as the diffuse hyper-dense area visible on the CT. A Planning Target Volume was constructed using a uniform 3 mm margin to account for residual positioning uncertainty caused by breathing motion. (This patient was not treated using the Synchrony motion tracking system). The bladder and cauda were defined as organs at risk, together with the left and right nerves branching from S1. A conformal treatment plan was developed using inverse optimization. This plan included 232 beams, each of 12.5 mm or 40 mm diameter. A dose of 16 Gy was prescribed to the 70% isodose and delivered in two fractions.



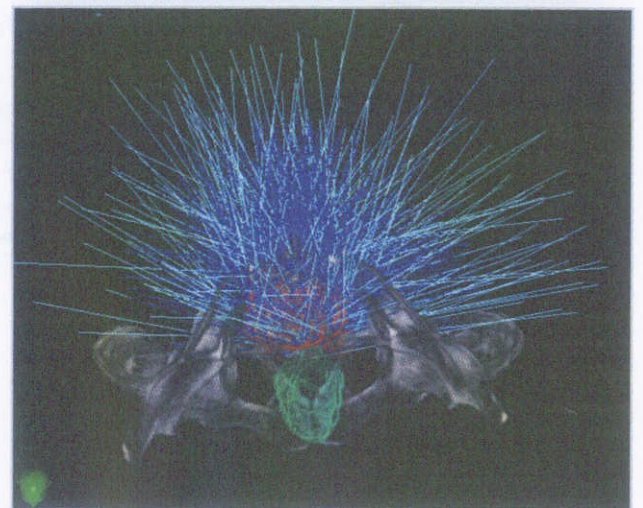
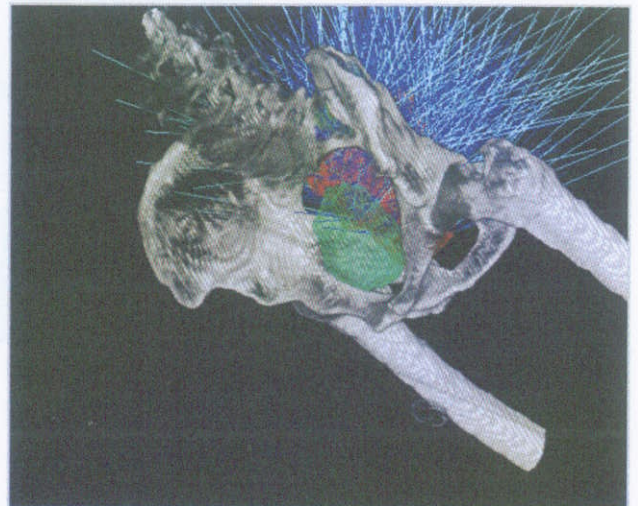Coronal section showing tight conformality of the prescription isodose to the large target volume.



The dose-volume histogram shows excellent sparing of the bladder and cauda equina, which are both adjacent to the PTV.

Treatment Delivery:

The patient was treated in April 2005 using the CyberKnife system with fiducial tracking. He was positioned prone using a vacuum formed immobilization device. The treatment was delivered in about two hours, including set-up. This was performed as an out-patient procedure.



3D views of the treatment plan, showing the beam arrangement and close proximity of the PTV (red) to the bladder (green).

RECURRENT RECTAL CARCINOMA

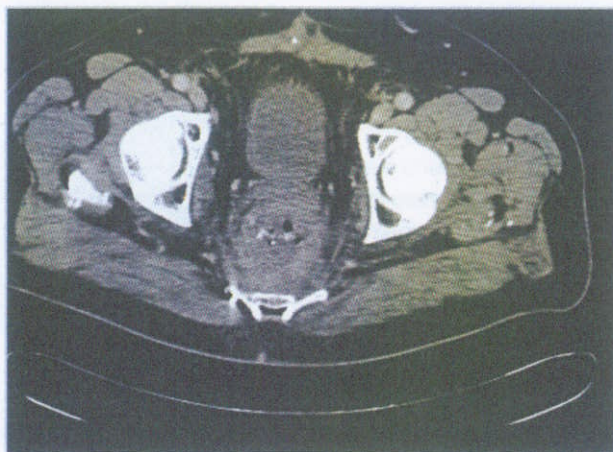
Outcome and Follow-Up:

On clinical examination in June 2005, the patient reported complete cessation of the sacral and leg pain. The rectal pain had changed in character but was still present. Rectal bleeding frequency had reduced significantly to once per week. Reduction of the tumor mass was apparent on digital rectal examination. The patient reported some grade 1 urinary complication (increased frequency) which ceased within one week post treatment. No acute complications were apparent.

A follow-up CT scan was performed at 3 months post treatment. Some reduction of the tumor volume was noted. Rectal edema was also reduced. By August 2005, the sacral pain and the radiating pain to the right leg remained absent and the rectal pain was reduced and intermittent. Rectal bleeding was completely resolved.

Conclusion and CyberKnife Advantages:

The CyberKnife system has delivered a painless treatment for recurrent rectal carcinoma. This has achieved significant symptom palliation and local control, with some tumor reduction. In such cases the treatment options are severely limited, and CyberKnife radiosurgery offers potentially significant clinical advantages over other alternatives.



3 month follow-up CT scan showing some reduction in the tumor volume. The edema of the rectum is also decreased.

ERASMUS UNIVERSITY MEDICAL CENTER / DANIEL DEN HOED CANCER CENTER (www.erasmusmc.nl)

The Erasmus Medical Center in Rotterdam is the largest university medical center in the Netherlands with 1200 beds, 33,000 new admissions and 165,000 initial outpatient visits per year. Its Daniel Den Hoed Cancer Center is one of the largest in Europe with a strong academic research program, and an international reputation for research and development. The department of Radiation Oncology is the largest in the Netherlands with 10 accelerators, an operating room for brachytherapy and its own nursing ward. The department has considerable experience in both intra- and extra- cranial radiosurgery with a major research focus in Image Guided High-Dose, High-Precision Radiation Therapy. The CyberKnife System, which entered clinical use in February 2005, is a key part of that clinical activity and research.

Acknowledgements:

M. Hol, P van der Baan, J. Pöll, J-B Prevost, L. Luthart, E. de Klerck, D. de la Bijl, R. Brandwijk, C. de Pan, M. Laarhoven, E. Sanderse