

PARA-AORTIC LYMPH NODE METASTASIS

CYBERKNIFE®
At  *Community Regional Medical Center*

CyberKnife® Team:
Radiation Oncologists: Douglas Wong, M.D., Ph.D., MPH
Urologist: Greg Rainwater, M.D.
Physicist: Georg Weidlich, Ph.D.
CyberKnife Therapists: Jeff Wallace, RTT
Valerie Cano, RTT
CyberKnife Coordinator: Laura Valenzuela, RN, BSN, OCN
CyberKnife Center: Community Regional Medical Center
Fresno, CA

PARA-AORTIC LYMPH NODE METASTASIS

DEMOGRAPHICS

Sex: Male
Age: 66 years
Histology: Metastatic Renal Cell Carcinoma

CLINICAL HISTORY

Referred by: Medical Oncologist
Past Medical History: Stage IV renal cell carcinoma, treated by radical nephrectomy one year prior

Case History

A 66-year-old male with a history of Stage IV renal cell carcinoma, treated with a left nephrectomy one year prior, presented with progressive left flank pain and findings of a large confluent left para-aortic lymph node mass on follow-up imaging studies. A CT-guided biopsy of the left para-aortic lymph node revealed metastatic carcinoma consistent with high-grade renal cell carcinoma. PET-CT scans revealed focal hypermetabolism in a region of confluent left para-aortic adenopathy, measuring 9.0 cm x 4.5 cm x 5.0 cm, with invasion of the adjacent psoas muscle (see Figure 1). At the time of the initial diagnosis of the renal cell carcinoma (Stage III, pT3N1M0) a radical nephrectomy had been performed to remove a 2-cm lesion involving the lower pole of the left kidney and a 5-cm mass in the mid-kidney that extended focally through the left renal capsule involving the perinephric fat. Lymph node sampling at the time of nephrectomy revealed one of four para-aortic lymph nodes positive for metastatic renal cell carcinoma. At the time a decision was made to follow these findings with PET-CT imaging.

CyberKnife® Treatment Rationale

Renal cell carcinoma has typically been treated primarily with surgical resection and has not responded well to treatment by conventional radiation therapy because of the inability to deliver high, tumoricidal doses of radiation to the tumor safely. The location of this large para-aortic mass as well as its intimate relationship with adjacent vasculature made surgical resection an unlikely option in this case. Treatment was attempted with multiple tyrosine kinase inhibitors to shrink the tumor but this therapy was not tolerated. CyberKnife® radiosurgery was chosen to allow delivery of high doses of radiation in a conformal manner to spare the adjacent critical structures while still delivering doses high enough to achieve tumor control. The CyberKnife System has successfully treated primary renal cell carcinomas,¹ as well as spinal metastases from renal cell carcinoma,² while preserving the surrounding tissue and critical structures.

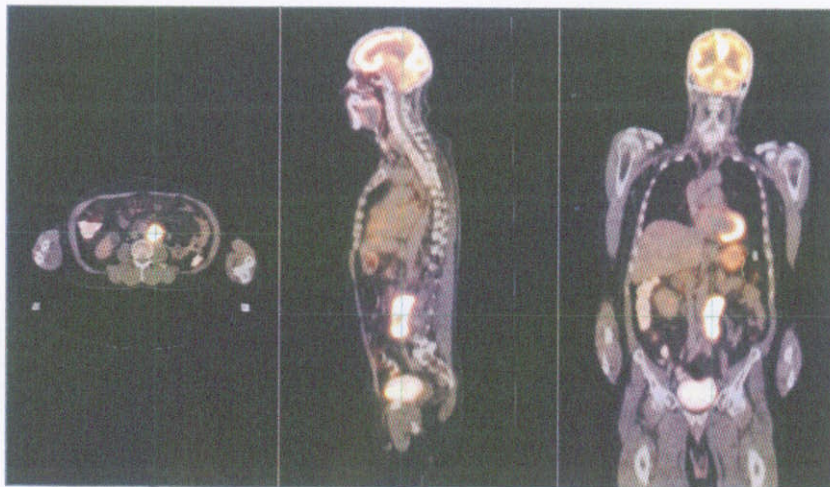


Figure 1. Pretreatment PET-CT scans revealed high FDG uptake in the region of the confluent left para-aortic adenopathy measuring 9.0 cm x 4.5 cm x 5.0 cm, with invasion of the adjacent psoas muscle.

TREATMENT DETAILS

Treatment Volume: PTV=99.9 cm³
Imaging Technique(s): CT
Rx Dose & Isodose: 24 Gy to 80%
Dose and Fractions: 8 Gy x 3 fractions
Number of Beams: 174

Number of Fiducials: 5
Treatment Time: 120 minutes/fraction
Tracking Method: Synchrony
Collimator(s): 25 mm
Tumor Coverage: PTV=97.7%

Planning Process

The patient was prepared for treatment planning by implanting five fiducials into the periphery of the tumor. A vac lock bag and knee sponge were used for immobilization. Contours of the GTV, PTV, right kidney, adjacent bowel and spinal canal were generated on the imaging studies. To protect adjacent small bowel, the PTV was deliberately made smaller than the GTV, accepting a dose gradient across the anterior rim of the GTV. A conformal treatment plan was developed using the MultiPlan® Treatment Planning System to cover 97.7% of the PTV and 86.2% of the GTV (see Figure 2).

Treatment Delivery

The patient received 24 Gy delivered in three fractions of 8 Gy over three days. The treatment was delivered to a volume of 99.9 cm³ (PTV), using 174 beams and a 25-mm collimator. The 80% isodose line provided 97.7% coverage of the PTV. The three outpatient treatments were accompanied by mild nausea that was relieved with oral compazine.


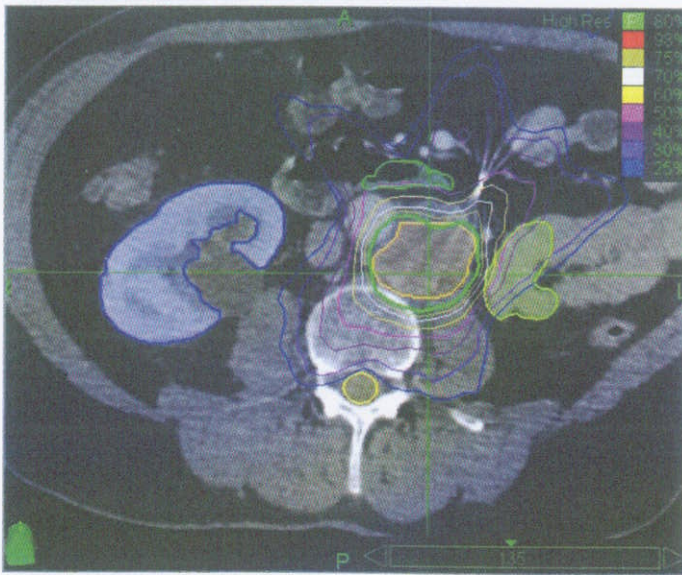


Figure 2. Left panel shows an axial view of the treatment plan developed using the MultiPlan® System. The 80% prescription isodose line is shown in green. Note high conformality and sparing of critical structures. The right panel shows a 3-D rendering of treatment beams as selected by the optimization algorithm.

Outcome and Follow-Up

- Two months following CyberKnife® treatment, a PET scan demonstrated a decrease in size of the para-aortic mass and decreased SUV from 7.5 to 2.2 (see Figure 3)
- Four months after CyberKnife treatment, a repeat PET scan revealed further decrease in SUV (from 2.2 to 1.7) within a decreasing left para-aortic nodal mass; no new areas of PET positivity SUV uptake were noted
- Fourteen months after CyberKnife treatment, a PET-CT scan revealed continued decrease in the size of the left para-aortic mass with SUV of 2.3 (Figure 4); the patient remains pain-free and enjoys normal activities without limitation

Conclusion and CyberKnife® Advantages

- This patient had an excellent initial outcome with the CyberKnife System for the treatment of a metastatic renal cell carcinoma to a para-aortic lymph node
- The CyberKnife System provided a convenient and minimally invasive treatment option for patients with metastasis to para-aortic lymph nodes

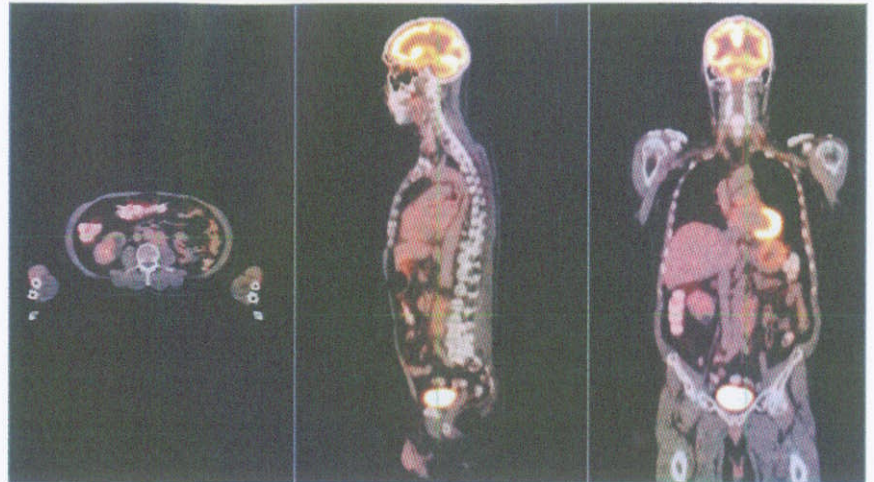


Figure 3. PET-CT scans obtained 2 months after CyberKnife treatment demonstrating a significant reduction in the FDG uptake in the region of the confluent left para-aortic adenopathy.

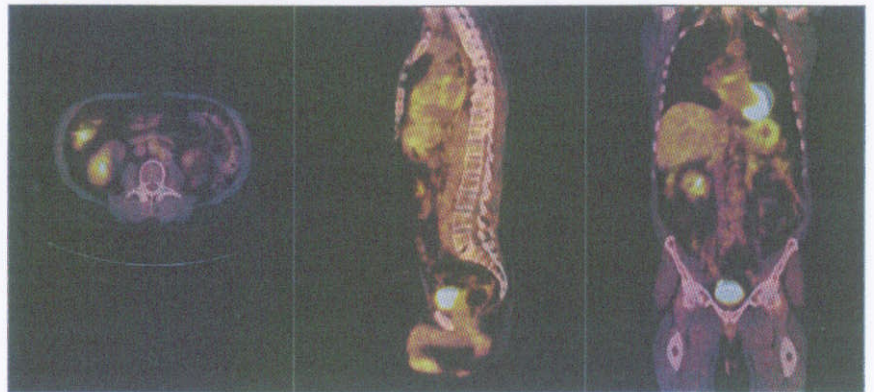


Figure 4. PET-CT scans obtained 14 months after CyberKnife treatment demonstrating a continued reduction in the FDG uptake in the region of the confluent left para-aortic adenopathy.

CYBERKNIFE CENTER AT COMMUNITY REGIONAL MEDICAL CENTER

The CyberKnife Center at Community Regional Medical Center in Fresno, California entered clinical service in the fall of 2005. Community's cancer program is one of the few in California with teaching-hospital level accreditation from the American College of Surgeons (ACOS) Commission on Cancer. At Community Regional in downtown Fresno we operate the only combined burn and Level 1 trauma center between Sacramento to Los Angeles, the only high-risk pregnancy unit in the region, and the state's largest and second busiest emergency department.

To contact us please visit our website at www.communitymedical.org or call (559) 447-3591.

References

1. Ponsky LE, Crownover RL, Rosen MJ, et al. Initial evaluation of Cyberknife technology for extracorporeal renal tissue ablation. *Urology* 2003;61:498-501.
2. Gerszten PC, Burton SA, Ozhasoglu C, et al. Stereotactic radiosurgery for spinal metastases from renal cell carcinoma. *J Neurosurg Spine* 2005;3:288-295.

