

## LOW-RISK ORGAN-CONFINED PROSTATE CANCER

---



NCH Regional Cancer Institute CyberKnife® Team:

Urologist: David M. Spellberg, M.D., FACS

Radiation Oncologist: Debra Freeman, M.D.  
Jay Friedland, M.D.

Medical Physicist: Mary Ellen Masterson-McGary, M.S.

CyberKnife Center: Naples Community Hospital  
Regional Cancer Institute  
Naples, FL

## LOW-RISK ORGAN-CONFINED PROSTATE CANCER

### DEMOGRAPHICS

**Sex:** M  
**Age:** 70  
**Histology:** Prostate Adenocarcinoma: stage T1c

### CLINICAL HISTORY

**Referred by:** Urologist  
**Past Medical History:** Transurethral resection of the prostate (TURP) for benign prostatic hyperplasia (BPH)

### Case History

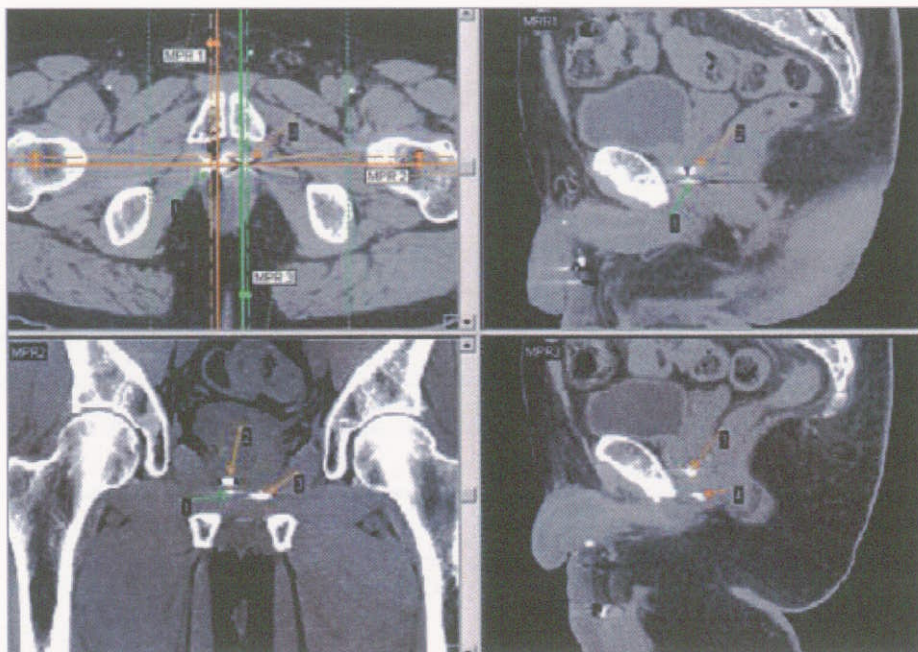
This 70-year-old male with a history of atrial fibrillation, hypertension and benign prostatic hyperplasia (BPH) presented with elevated prostate specific antigen (PSA) of 4.5 ng/ml in January 2005. He had been followed by his urologist for the previous six years with regular PSA monitoring. He had no family history of prostate cancer and underwent a TURP 2 years prior for BPH. His atrial fibrillation and hypertension were managed by Coumadin, Toprol, Lanoxin and Zestoretic.

The patient's symptoms included nocturia times two and a history of erectile dysfunction. Patient denies a history of dysuria, hematuria, urinary incontinence, urinary urgency, urinary frequency or hesitancy. Transrectal ultrasound (TRUS) guided biopsy revealed adenocarcinoma of the prostate in 6 of 12 biopsy cores, all of which were less than 5% positive and a Gleason score of 3 + 3. Tumor was found in both lobes of the prostate, and was staged cT1c by digital rectal examination. A CT scan of the abdomen / pelvis was unremarkable and a bone scan was negative for metastatic disease.

### CyberKnife® Treatment Rationale

The patient was evaluated by Urology and Radiation Oncology for his prostate cancer. Treatment options included surgery, external beam radiation therapy (IMRT, conformal) and CyberKnife monotherapy. The patient wanted a less invasive and convenient therapy in order to continue his work and day to day activities and therefore elected for CyberKnife monotherapy.

Current literature suggests that prostate cancer will respond favorably to hypofractionated radiotherapy due to the low  $\alpha/\beta$  ratio of prostate cancer.<sup>1,2</sup> Several groups have demonstrated that hypofractionation schemes for prostate cancer achieve excellent local control with minimal toxicity to the urethra and rectum.<sup>3,4</sup> CyberKnife stereotactic radiosurgery has been shown to decrease prostate tumor volume and decrease PSA levels of human prostate cancer cells in a mouse model.<sup>5</sup> Initial studies of CyberKnife monotherapy have shown beneficial effects, including decreased PSA results and minimal or no toxicities in patients with organ-confined prostate cancer.<sup>6</sup>



Multiplanar pre-treatment planning images show all 4 fiducial markers placed within the prostate.

**TREATMENT DETAILS**

**Prostate Volume:** 29.5 cc  
**Imaging Technique(s):** CT  
**Rx Dose & Isodose:** 35 Gy to 82%  
**Conformality Index:** 1.39  
**Tumor Coverage:** 95%  
**Number of Beams:** 130

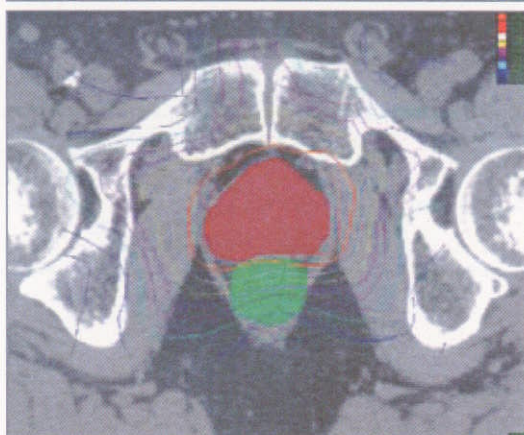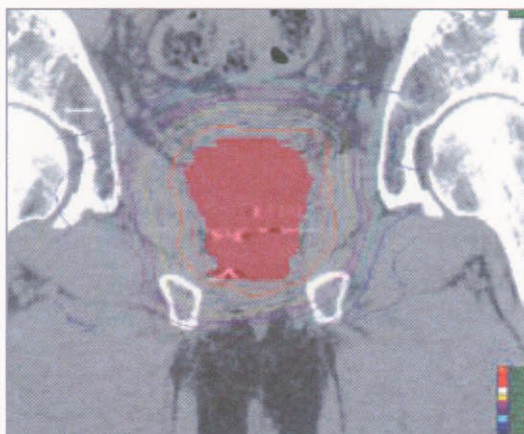**Fractions / Treatment Time:** 5 @ 43 min per fraction  
**Path Template:** 3 path 900\_1000 mm  
**Tracking Method:** Fiducial  
**Collimator(s):** 20 mm and 35 mm

**Treatment Planning Process**

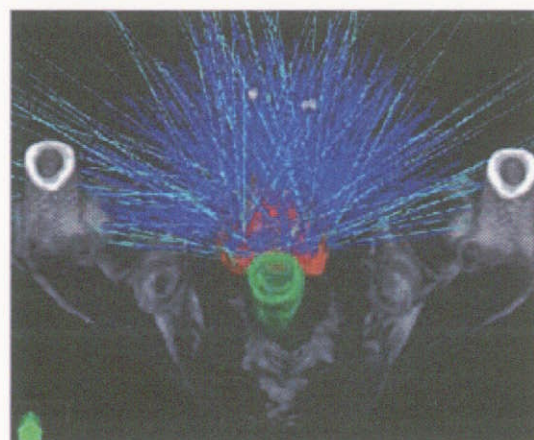
In March 2005, four fiducial markers were placed under intravenous conscious sedation in the prostate by the urologist using a TRUS-guided template. A CT study was performed with the patient in the treatment position using a custom immobilization device. The fiducial locations were identified and the prostate and critical structures (rectum, bladder, and urethra) were contoured. The planning target volume (PTV) included the prostate with a 5-mm margin in all directions except for a smaller 3-mm posterior margin to decrease dosage to the rectum. Treatment planning was designed to encompass 95% of the target volume and minimize dose to critical structures.

**Treatment Delivery**

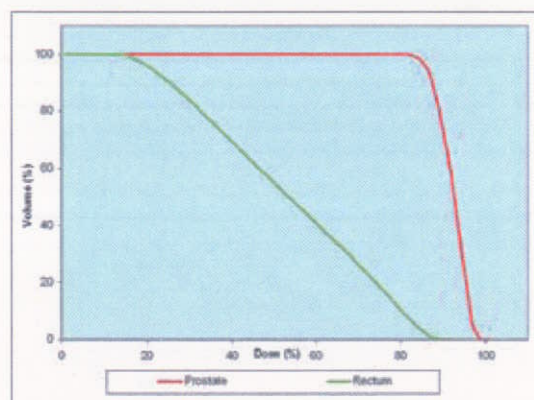
The patient began treatment in April 2005. A prescription dose of 35 Gy was delivered in 5 fractions over 5 consecutive days to the 82% isodose line. Two collimator sizes were used and a conformality index of 1.39 was achieved. There were 130 beams from 111 nodes delivered in an average of 43 minutes. Following the fourth treatment, the patient experienced nocturia and was given 0.4 mg Flomax with resolution of symptoms. The patient reported mild urinary frequency and mild urgency 5 days after completion of last fraction of radiosurgery and was treated with Pyridium with resolution of symptoms. Overall, the patient tolerated the treatment well.



Coronal and axial treatment plans showing the 82% prescription isodose line relative to the prostate (red). Lower percentage isodose lines demonstrate sparing of the rectum (green).



Inferior-superior 3D of bony anatomy and CyberKnife beam positions showing treated tumor with rectal sparing.



Dose-Volume Histogram (DVH) for prostate.

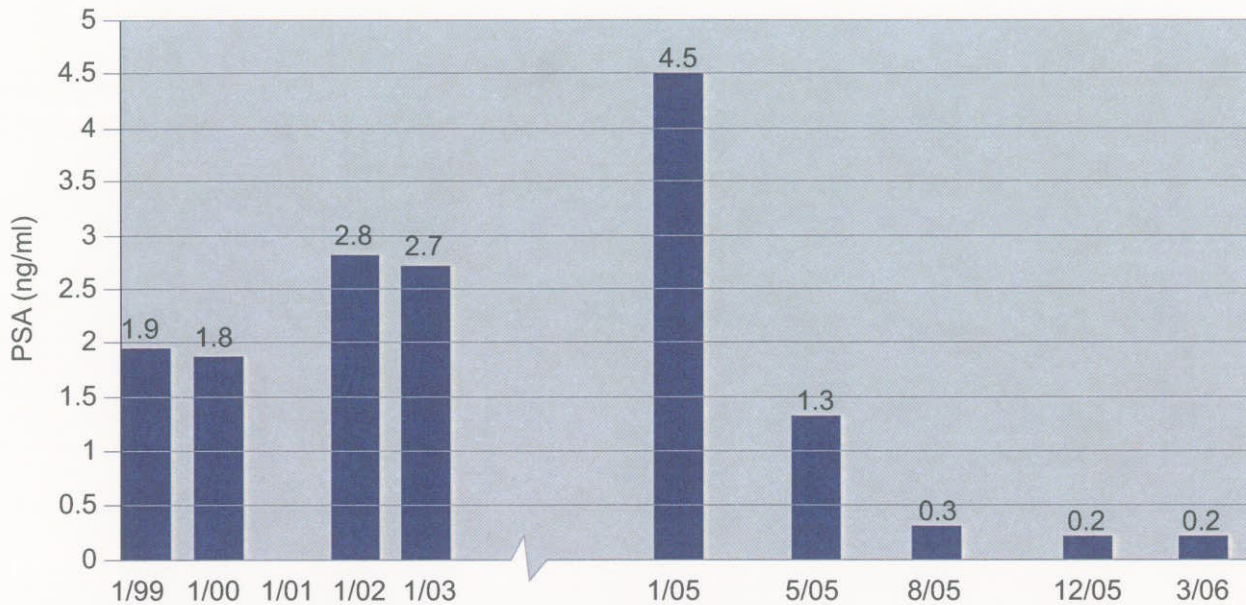
## LOW-RISK ORGAN-CONFINED PROSTATE CANCER

### Outcome and Follow-Up

- The patient responded to CyberKnife® treatment with a decrease in PSA value from 4.5 ng/ml to 1.3 ng/ml at one month following radiosurgery and to 0.2 ng/ml at 8 months. At 1 year following treatment, PSA remains stable at 0.2 ng/ml
- The patient experienced mild acute urinary toxicities which resolved with medication
- There were no reported acute rectal toxicities
- At 1-year follow-up, there were no chronic urinary or rectal toxicities

### Conclusion and CyberKnife Advantages

- CyberKnife monotherapy produced an early and stable reduction in PSA in a patient with low-risk organ-confined prostate cancer with minimal acute urinary toxicities and no noted chronic toxicities to date
- CyberKnife treatment provides a convenient, minimally invasive option for patients with early-stage, organ-confined prostate cancer



There is a significant reduction in PSA post CyberKnife treatment with a stable PSA of 0.2 ng/ml at 12 months.

### NAPLES COMMUNITY HOSPITAL / NCH HEALTHCARE SYSTEM ([www.nchmd.org](http://www.nchmd.org))

The CyberKnife at Naples Community Hospital / NCH Healthcare System entered clinical service in the summer of 2004. Clinical use is currently 46% intracranial and 54% extracranial. The NCH Regional Cancer Institute (<http://cancer.nchmd.org/>) provides promising clinical trials and cancer research. NCH Healthcare System is a comprehensive cancer program and The Cancer Institute provides patients with quality care supported by state of the art technology highlighted by the CyberKnife System.

### References

1. Brenner DJ and Hall EJ. Fractionation and Protraction for Radiotherapy of Prostate Carcinoma. Int J Radiat Oncol Biol Phys 43: 1095-1101, 1999.
2. King CR and Cotrutz C. Hypofractionated Radiotherapy for Localized Prostate Cancer: Therapeutic Rationale and Feasibility of the CyberKnife. Robotic Radiosurgery – Volume 1, 315-323, CyberKnife Society Press, 2005.
3. Martinez A, Pataki J, Edmundson G, Sebastian E, Brabbins D, Gustafson G. Phase II Prospective Study of the Use of Conformal High-Dose Rate Brachytherapy as Monotherapy for the Treatment of Favorable Stage Prostate Cancer: a Feasibility Report. Int J Rad Oncol Phys Biol 49: 61-69, 2001.
4. Yoshioka Y, Nose T, Yoshida K, Oh RJ, Yamada Y, Tanaka E, Yamazaki E, Inoue T, Inoue T. High-Dose Rate Brachytherapy as Monotherapy for Localized Prostate Cancer: a Retrospective Analysis with Special Focus on Tolerance and Chronic Toxicity. Int J Rad Oncol Biol Phys 56: 213-220, 2003.
5. Lotan Y, Stanfield J, Cho C, Sherwood J, Abdel-Aziz KF, Chang C, Forster K, Kabbani W, Hsieh J, Choy H, Timmerman R. Efficacy of High-Dose per Fraction Radiation for Implanted Human Prostate Cancer in a Nude Mouse Model. J Urology 175: 1932-1936, 2006.
6. Jo MK, Park K, Kim KH, Cho CG, Lee C. Feasibility of CyberKnife for the Treatment of Localized Prostate Cancer: Preliminary Results: presented at the American Urological Association annual meeting, Atlanta, GA, May 2006, Abstract # 1167.

